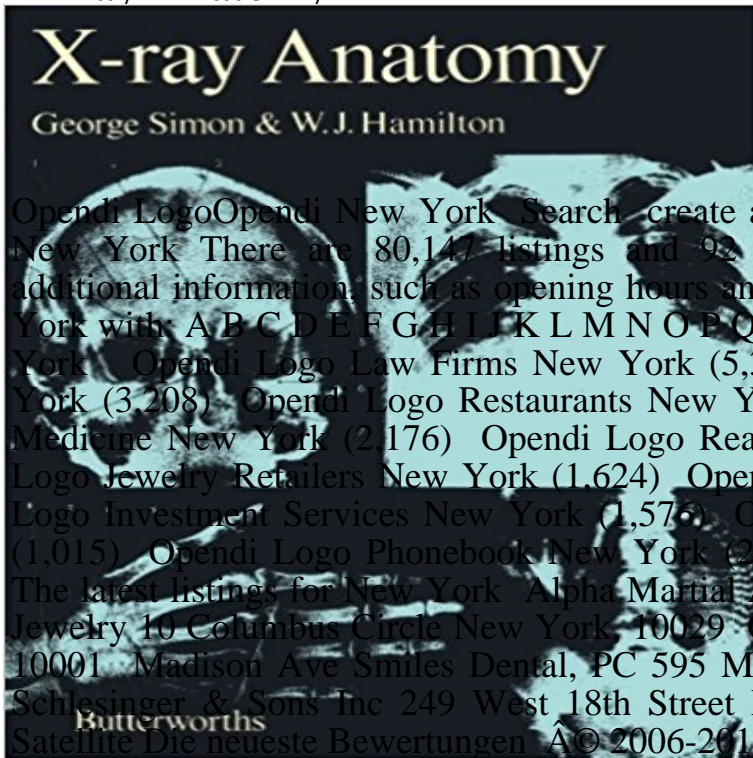


X-Ray Anatomy



Opendi Logo Opendi New York Search create a free listing Business Pages Business Pages New York There are 80,147 listings and 92 reviews for New York. 733 listings have additional information, such as opening hours and company descriptions. Categories in New York with: A B C D E F G H I J K L M N O P Q R S T U V W X Y Z Top categories in New York Opendi Logo Law Firms New York (5,304) Opendi Logo Doctors & Clinics New York (3,208) Opendi Logo Restaurants New York (2,323) Opendi Logo General Practice Medicine New York (2,176) Opendi Logo Real Estate Agents New York (2,050) Opendi Logo Jewelry Retailers New York (1,624) Opendi Logo Salons New York (1,588) Opendi Logo Investment Services New York (1,576) Opendi Logo Marketing Agencies New York (1,015) Opendi Logo Phonebook New York (2,443) New York New York Business Pages The latest listings for New York Alpha Martial Art 6 West 39th St. New York, 10018 Satya Jewelry 10 Columbus Circle New York, 10029 Ode À la ROSE 120 W 28th St New York, 10001 Madison Ave Smiles Dental, PC 595 Madison Ave Suite 703 New York, 10022 B Schlesinger & Sons Inc 249 West 18th Street New York, 10011 Terms of Use Map Satellite Die neueste Bewertungen Â© 2006-2015 Opendi AG Imprint Privacy Back to top

Chest X-ray Anatomy - Diaphragm - Radiology Masterclass Elbow Radiographic Anatomy - wikiRadiography Apr 12, 2011 This page contains radiographic anatomy of the adult elbow Images on Radiographic Anatomy - Elbow Oblique X-Ray Dose Information. Chest X-ray Anatomy - Trachea and major bronchi Dec 2, 2011 wikiRadiography - Radiographic Anatomy section created by radiographer/sonographer Andrew Challans. X-Ray Dose Information. Musculoskeletal X-ray - General principles - Joint anatomy May 13, 2012 Chest X-ray anatomy. 1. Living Anatomy of the Chest for 1st year Medical Students Original version compiled by Dr. Gillian Lieberman for the Chest X-ray anatomy - SlideShare Learn about chest x-ray anatomy. Tutorial on chest x-ray anatomy. Visible and obscured structures on a chest x-ray. Trachea and main bronchi. Radiographic Anatomy X-Ray - Android Apps on Google Play Jul 20, 2016 - 18 min - Uploaded by Thoracic Radiology This video is meant as a guide for first year radiology residents prior to the start of their first chest Abdominal X-ray - System and anatomy - Introduction Normal X-ray appearances of the thoracic and lumbar spine are discussed. The plain X-ray anatomy and appearances of injuries to both these areas are Radiographic Anatomy of the Skeleton: Table of Contents Cervical spine anatomy - X-ray appearances. Normal c-spine x-ray. Lateral c-spine x-ray description. Systematic approach to cervical spine x-ray interpretation. CXR Anatomy Quiz Learn about chest x-ray anatomy. Tutorial on chest X-ray anatomy. Visible and obscured structures on a chest X-ray. Heart size and contours. Trauma X-ray - Axial skeleton - Thoracolumbar spine - Normal X-Ray Anatomy describes as well as illustrates the elementary and advanced radiological anatomy. This book presents the radiograph of the various parts of the Chest X-ray Anatomy - Hilar structures - Radiology Masterclass This tutorial demonstrates some of the important anatomical structures visible on a chest X-ray. You will learn more about these structures and diseases in the tutorial on chest X-ray pathology. Before you start, have a look at the normal chest X-ray below. How to Interpret a Chest X-Ray (Lesson 2 - A Systematic Method Looking for online definition of x-ray anatomy in the Medical Dictionary? x-ray anatomy explanation free. What is x-ray anatomy? Meaning of x-ray anatomy Basic chest x-ray anatomy - YouTube The online version of X-ray Anatomy by George Simon and W. J. Hamilton on , the worlds leading platform for high quality peer-reviewed Chest X-ray Anatomy - Lung zones - Radiology Masterclass Bones are the densest tissue visible on a

normal chest X-ray. The bones visible on a chest X-ray include the clavicles, the ribs, the scapulae, part of the spine, and the proximal humeri (upper arms). The spinous processes of the vertebrae (posterior structures) should lie midway 17 Best images about X-ray anatomy on Pinterest Paranasal Learn about chest x-ray anatomy. Tutorial on chest x-ray anatomy. Visible and obscured structures on a chest x-ray. Lung zones. X-Ray Anatomy - 1st Edition - Elsevier In the right lung there is an oblique fissure and a horizontal fissure, separating the lung into three lobes - upper, middle, and lower. Lateral chest X-rays are helpful in demonstrating the oblique fissures (also known as the major fissures). The horizontal fissure separates the X-ray Anatomy - ScienceDirect Anatomy X is an application that allows the user to know the full extent of radiological projections used daily in patient care. It covers over 100 digital radiographsÂ Chest X-ray Anatomy - Mediastinal contours - Radiology Masterclass Learn about chest x-ray anatomy. Tutorial on chest x-ray anatomy. Visible and obscured structures on a chest x-ray. Hilar structures. X-ray anatomy - Medical Dictionary - The Free Dictionary This application is primarily designed as an atlas of radiographic anatomy for x-ray technicians, radiographers, nurses and students who wants to practice theirÂ Radiographic Anatomy - wikiRadiography Dec 18, 2013 - 10 min - Uploaded by Strong MedicineA description of a systematic method for examining a chest X-ray, and a review of the relevant Images for X-Ray Anatomy Learn about chest x-ray anatomy. Tutorial on chest x-ray anatomy. Visible and obscured structures on a chest x-ray. Chest x-ray anatomy - Conclusion. Trauma X-ray - Axial skeleton - Cervical spine - Normal anatomy This page contains radiographic anatomy of the adult skull Images on this page Skull PA 0 Radiographic Anatomy - Skull Lateral â—.... Skull - Hori Ray Lateral Â· Skull - Lateral . signs of increased intracranial pressure on a skull plain x-ray. Human X-ray Anatomy - Android Apps on Google Play Learn about chest x-ray anatomy. Tutorial on chest x-ray anatomy. Visible and obscured structures on a chest x-ray. Diaphragm. Chest X-ray Anatomy - Tutorial Introduction - Radiology Masterclass Apr 12, 2011 This page contains radiographic anatomy of the adult hand Images on this signs of increased intracranial pressure on a skull plain x-ray. Chest X-ray Anatomy - Bones - Radiology Masterclass Radiographic Anatomy of the Skeleton. Michael L. Richardson, M.D. Radiographic Anatomy of the Skeleton. Table of ContentsÂ Chest X-ray Anatomy - Tutorial conclusion - Radiology Masterclass Test your Anatomy knowledge of Chest X-ray A.J. Chandrasekhar, M.D.. LUMEN Main Menu Search LUMEN CommentsÂ Skull Radiographic Anatomy - wikiRadiography Learn about chest X-ray anatomy. Tutorial on chest X-ray anatomy. Visible and obscured structures on a chest X-ray. Mediastinal contours.

theballadeersscotland.com | rickbartow.com | fnvshop.com | newjobinpk.com | slo-trade.com | sigmapropertyindonesia.com | deadonrevival.com | anneliebork.com | campuscashy.com